



Percutaneous Image-Guided Breast Biopsy

- Image-guided biopsy is indicated for both palpable and non-palpable breast lesions suspicious for malignancy and is a cost-effective procedure that reduces the number of surgeries
- Ultrasound-guided biopsy allows real-time imaging, can be performed without breast compression, and is the preferred method if the lesion is detectable with ultrasound
- Stereotactic (mammographic) biopsy is used primarily for microcalcifications and for masses not visible with ultrasound
- MRI-guided biopsy is used for suspicious areas of contrast enhancement that cannot be seen on ultrasound or mammography

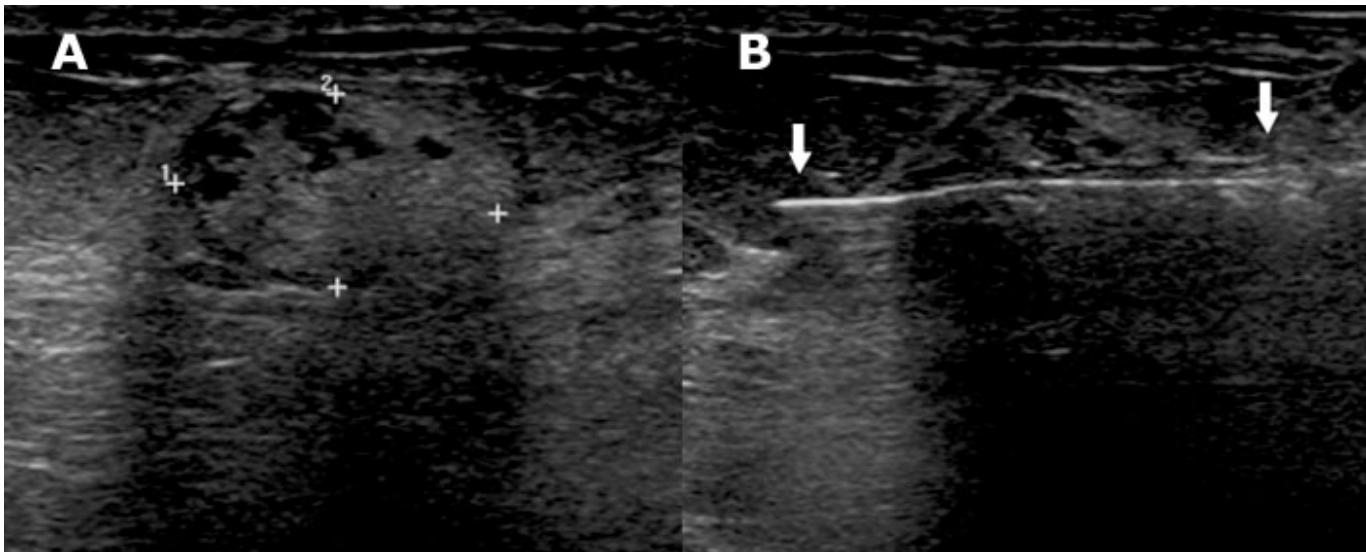


Figure 1. Ultrasound-guided biopsy of breast lesion. The diagnostic study (A) shows a solid lesion (calipers) suspicious for cancer. An image during the biopsy (B) shows the core biopsy needle (arrows) sampling the lesion.

Percutaneous image-guided breast biopsies are rapid, minimally invasive procedures that make surgery unnecessary for a large majority (70-80%) of patients whose lesions will prove to be benign. The image-guided biopsies are performed under local anesthetic with no need for conscious sedation using a small incision that requires no stitches to close. The procedures do not deform the breast and cause minimal to no scarring on subsequent mammograms. Complications, such as hematoma and infection are rare, occurring in less than 1 per 1000. Patients diagnosed with breast cancer by image-guided biopsy will require fewer surgeries, on average, than those diagnosed by surgical biopsy. Thus, percutaneous

image-guided breast biopsies are both medically preferable and cost-effective and have largely replaced surgical biopsies for pathologic diagnosis.

Image-guided biopsy is recommended for almost all cases of suspected breast cancer (BI-RADS 4-5), whether or not the patient is symptomatic or the lesion palpable. Women who have palpable lesions not visible by imaging are biopsied surgically. Because percutaneous biopsy requires that the patient have normal coagulation rates, surgical biopsy may be considered in patients taking coumadin to minimize their time off medication.

Even if imaging prior to intervention shows a very high likelihood of malignancy, image-guided biopsy can provide useful information for surgical planning. In addition to confirming the diagnosis, biopsy can sometimes reveal multifocal (multiple sites within same quadrant) or multicentric (multiple sites within different quadrants) carcinoma. Knowing that the lesion is definitively a cancer allows the surgeon to sample axillary nodes for metastasis at the time of definitive excision. In addition, the likelihood of attaining clear margins at the first operation after

percutaneous diagnosis of cancer is 75-100%, compared to 45-64% when a diagnosis has not been established, thereby sparing additional surgery in a significant number of patients.

Percutaneous image-guided biopsy may be performed under ultrasound, stereotactic, or MRI guidance. The selection of modality depends on the imaging characteristics of the lesion. Some advantages and disadvantages of the alternate procedures are listed in Table 1.

Table 1. Advantages and Disadvantages of Percutaneous Breast Biopsy Methods

Biopsy Method	Advantages	Disadvantages
Ultrasound-guided	Real-time visualization of biopsy needle Accessibility of all areas of breast and axilla Multidirectional sampling possible Low cost	Can only be performed if lesion is sonographically evident Difficulty in confirming lesion retrieval
Stereotactic	Can be used for almost all lesions visualized on mammograms X-ray of biopsy specimen confirms that targeted lesion was sampled	No real-time visualization of biopsy needle Discomfort from breast compression Must have arms raised up; may not be possible for patients with limited shoulder movement Must have adequate compressed breast thickness to allow biopsy
MRI-guided	Can be performed when lesions are visible on MRI but not on other modalities.	Transient contrast enhancement may limit ability to see lesion Difficult to confirm lesion retrieval

Ultrasound-Guided Biopsy

Ultrasound guidance is the method of choice for all patients when the lesion can be visualized by this modality (Figure 1). This method is easiest for both patient and operator because, unlike the other techniques, the lesion can be sampled without breast compression while the patient is reclining in the supine position. Under real-time imaging guidance, a radiologist inserts a core biopsy needle into the lesion and withdraws multiple samples. The sensitivity and specificity of this procedure for detecting malignancy has been reported to be 97% and 100%, respectively.

A radiographically visible clip, 1-2 mm in size, is sometimes placed after the biopsy sample is removed to mark the site from which the sample was taken in case further surgery is needed. Placement of a clip is considered if the targeted lesion is <5 mm in size, because the lesion remaining after biopsy may be too small to find by ultrasound. A clip will also be placed if the patient is a likely candidate for neoadjuvant therapy; that is if a lesion is ≥3 cm and the imaging characteristics are highly suggestive of malignancy. In these cases, chemotherapy may cause the tumor regression to the point where it is no longer evident on imaging. The presence of a clip allows accurate localization of the tumor at the time of surgical excision.

Stereotactic (Mammographic) Biopsy

Mammographic calcifications, a potential sign of malignancy, are generally not visible by ultrasound; for these lesions stereotactic biopsy is the method of choice. For this procedure, the patient must lie prone on a special table, which is elevated to allow access to the breast from below. The breast is held in compression while stereotactic x-ray images are taken, the 3-dimensional location of the lesion determined, and the optimal path to the lesion calculated. A computer-guided needle is inserted to the calculated position and a second pair of stereotactic images confirms the position of the needle. Once the lesion has been biopsied, radiographic demonstration of the originally targeted lesion in the specimen confirms sampling validity. If the target lesion is not present, the procedure can be repeated. In the vast majority of cases, marker clips are placed immediately after biopsy because the lesion may no longer be visible radiographically. The sensitivity and specificity of stereotactic biopsy for detecting malignancy has been reported to be 95% and 97%, respectively.

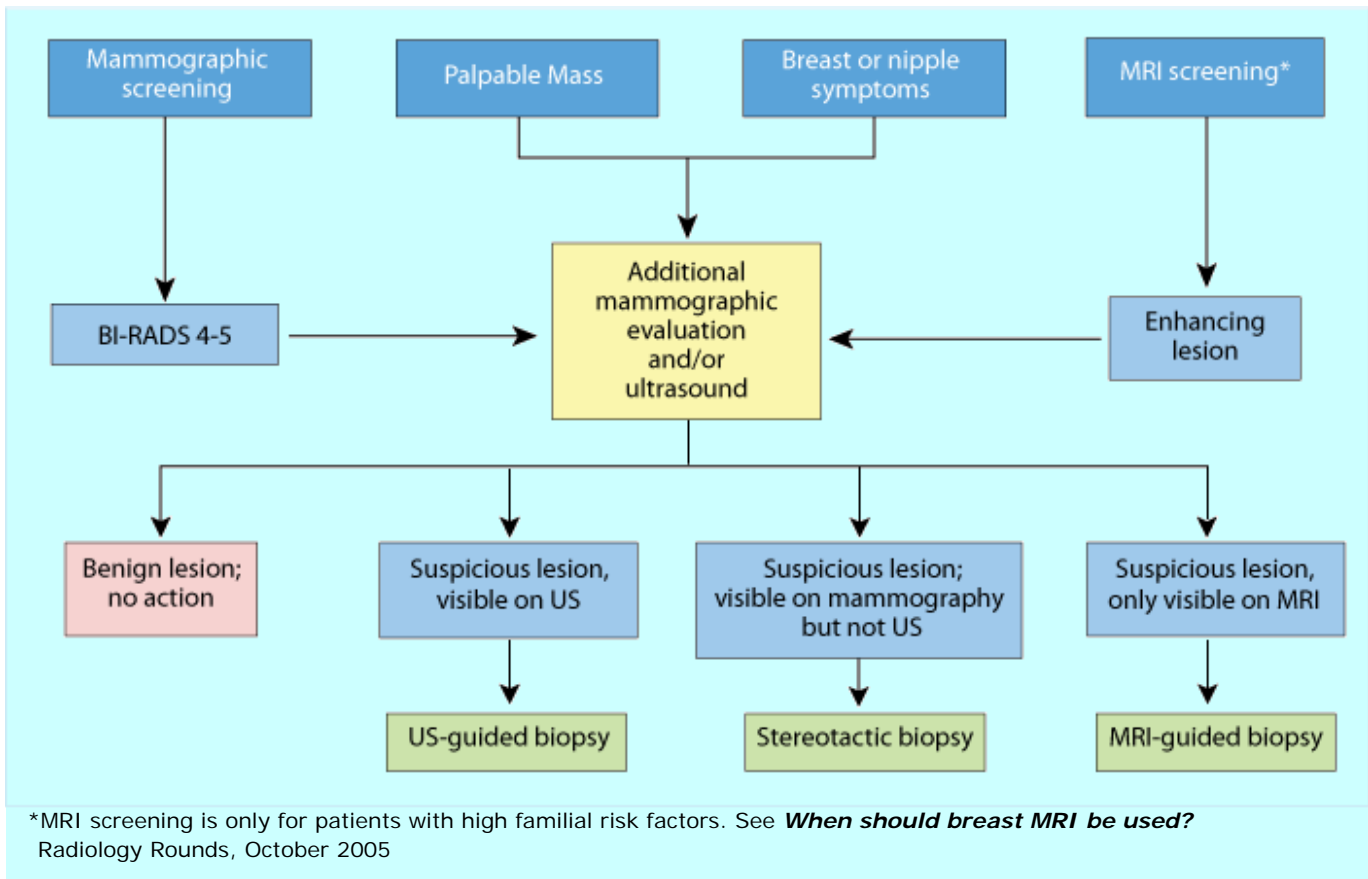


Figure 2. Algorithm for the selection of the appropriate image-guided biopsy modality.

MRI-Guided Biopsy

MRI-guided biopsy is only used when suspicious lesions can be visualized with this modality but not with mammography or ultrasound. The patient lies prone with her breasts positioned in a dedicated breast MRI coil and stabilized with moderate compression in a biopsy guidance grid. After a localizing scan, the patient table is moved out of the bore of the magnet to allow access to the breast. A biopsy sheath is inserted into the calculated position of the lesion and a second scan confirms the correct position of the sheath. The table is again moved out of the magnet bore and a biopsy sample withdrawn with a vacuum assisted device and an MRI-safe marker clip placed to denote the site of biopsy should surgery be needed. A final scan of the biopsied region verifies the location of the sampling site and marker clip. Reports of the technical success rate range from 95-100%. The reported cancer yield is 20-55% in the population who undergo this procedure.

Histological Concordance

Image-guided biopsies are not considered complete until the result from histological analysis is shown to be in agreement with the suspected radiologic diagnosis. This process is known as establishing radiologic-pathologic concordance. If the histological results do not agree with the radiologic assessment (discordance),

the lesion must be surgically excised for pathologic certainty. In addition, if there are findings of atypical ductal hyperplasia, lesion resection is warranted because surgical findings may upgrade the lesion to ductal carcinoma in situ or invasive carcinoma.

Scheduling and Patient Management

Once identified as a candidate for percutaneous image-guided biopsy, the patient meets with the Breast Imaging Nurse Coordinator, who will explain the details of the upcoming procedure, answer the patient's questions, and coordinate a time for her biopsy. Alternatively, breast biopsy procedures can be scheduled by calling 617-726-3094.

Further Information

For further questions on percutaneous breast biopsy, please contact [Elizabeth Rafferty, M.D.](#), Acting Director of Breast Imaging, at 617-726-3093.

We would like to thank Dr. Rafferty and Michelle C. Specht, M.D., Surgical Oncology, for their advice and assistance in the preparation of this article.

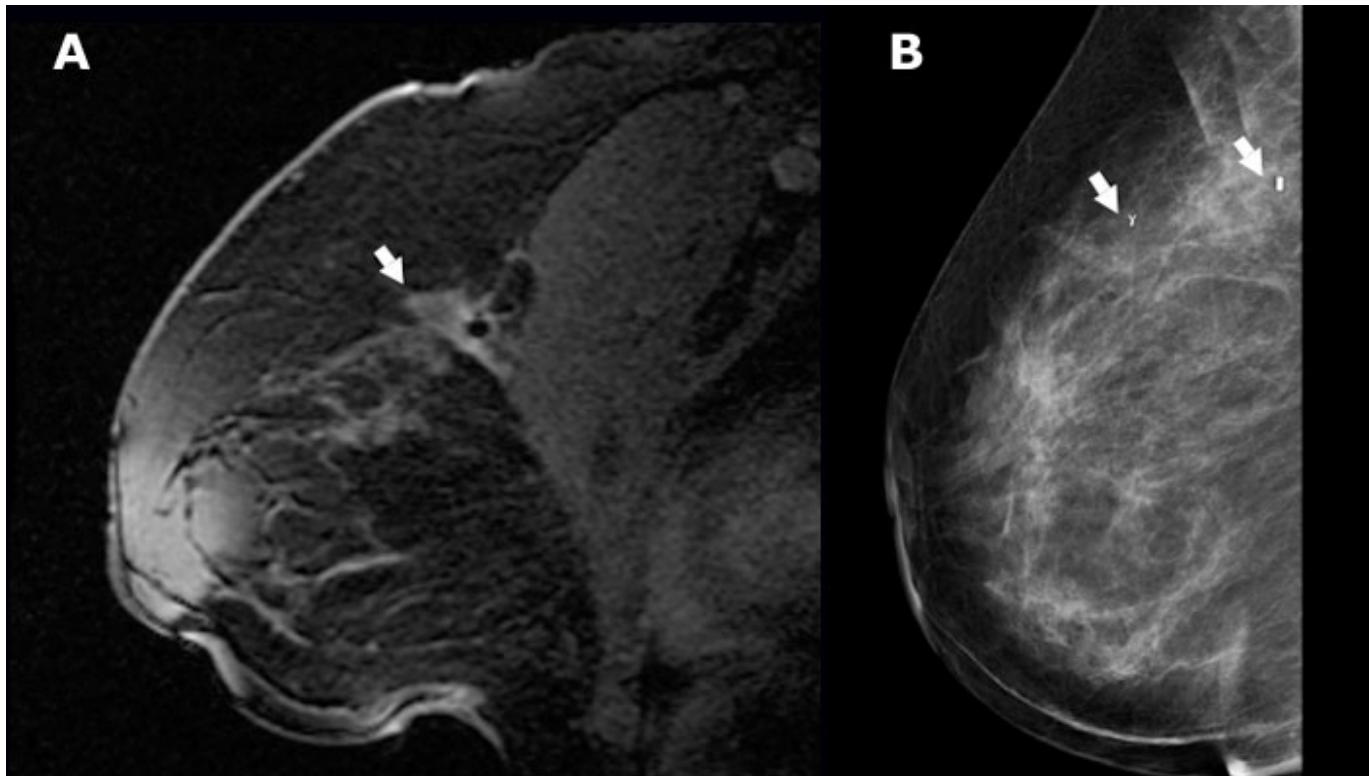


Figure 3. MRI-guided biopsy. The diagnostic MR image (A) demonstrates an area of abnormal contrast enhancement (arrow). Mammogram following the biopsy (B) shows the clips (arrows) placed to mark the biopsy site.

References

- Fajardo, L, Pisano, E, Caudry, D, Gatsonis, C, Berg, W, Connolly, J, Schnitt, S, Page, D, McNeil, B and Radiologist Investigators of the Radiologic Diagnostic Oncology Group V. (2004) *Stereotactic and sonographic large-core biopsy of nonpalpable breast lesions: results of the Radiologic Diagnostic Oncology Group V study.* Acad Radiol **11**: 293-308
- Liberman, L. (2002) *Percutaneous image-guided core breast biopsy.* Radiol Clin North Am **40**: 483-500
- Nurko, J and Edwards, MJ. (2005) *Image-guided breast surgery.* Am J Surg **190**: 221-7
- Perlet, C, Heywang-Kobrunner, SH, Heinig, A, Sittek, H, Casselman, J, Anderson, I and Taourel, P. (2006) *Magnetic resonance-guided, vacuum-assisted breast biopsy: results from a European multicenter study of 538 lesions.* Cancer **106**: 982-90
- Simon, JR, Kalbhen, CL, Cooper, RA and Flisak, ME. (2000) *Accuracy and complication rates of US-guided vacuum-assisted core breast.* Radiology **215**: 694-7
- Verkooijen, HM. (2002) *Diagnostic accuracy of stereotactic large-core needle biopsy for nonpalpable breast disease: results of a multicenter prospective study with 95% surgical confirmation.* Int J Cancer **99**: 853-9