



Image-Guided Pain Management, Part 2: Steroid/Anesthetic Injections for Musculoskeletal Pain

- Image-guided injection of a short-acting anesthetic and anti-inflammatory steroid can be useful in the management of patients with pain that has not resolved after conservative therapy
- These injections can be used to
 - Resolve pain faster than would occur with rest and medication
 - Control pain in non-surgical candidates
 - Diminish symptoms in order to enable patients to undergo physical therapy or exercise program to strengthen surrounding musculature
 - Diagnose site of pain source
 - Obviate or delay surgical intervention

Inflammation in the musculoskeletal system is a common source of pain. When symptoms do not respond to conservative treatment, image-guided injection of a combination of short-acting anesthetic and anti-inflammatory steroid can often offer relief, especially in patients with acute exacerbation of symptoms. In joints and spine, the anesthetic can provide immediate pain relief that lasts 4-5 hours and confirms the source of pain. The steroid begins to work after 1-2 days and reaches maximum effectiveness in 5-7 days. The duration of pain relief varies depending on many factors, including the severity and reversibility of the patient's condition. Radiologists, anesthesiologists, and physiatrists perform most image-guided pain management procedures at MGH and Spaulding Rehabilitation Hospital.

The injection is effective to the extent that symptoms are caused by inflammation and the steroid can be delivered to the proper location. Bursal and intra-articular inflammation may result from many causes, such as physical activity and degenerative processes. In the spine, inflammation may be associated with disk herniation, degenerative disk disease and facet arthropathy. Unfortunately, it is unlikely that the steroid has any long-term effect on the natural history of the underlying disease. It will not shrink a herniated disk, reverse degenerative change, or prevent future episodes of inflammation and pain.

In the setting of acute or subacute symptoms, steroid administration can speed recovery and enable the return to normal daily activities, thereby limiting or preventing muscular weakening. In other cases, an injection can decrease symptoms sufficiently to allow the patient to begin physical therapy or initiate an exercise program that strengthens the musculature,

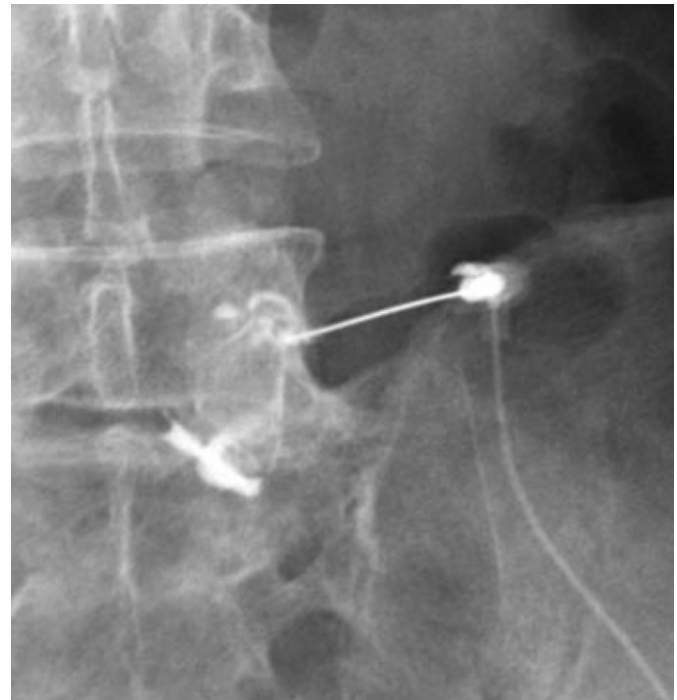

Figure 1. The patient had persistent right lower back and buttock pain. MRI showed L5-S1 facet arthropathy without substantial disk disease. The fluoroscopy image shows the needle placed in the right L5-S1 facet joint with contrast material outlining the joint capsule. The anesthetic agent decreased symptoms immediately, providing diagnostic information about the L5-S1 facet. Medial branch block was subsequently performed.

improves postural control, and alleviates future symptoms. In patients who are not surgical candidates, repeated injections can help to control

symptoms and improve quality of life. Several injections can be performed over the course of a year. There are few or no long-term consequences of repeated steroid injections.

The injection target may be obvious or subtle. Clinical history and physical examination are correlated with imaging findings. Magnetic resonance imaging, for example, may show a bursal collection or joint effusion that confirms the best location for steroid administration. In the spine, imaging commonly demonstrates multiple CT or MR abnormalities even in asymptomatic individuals. Therefore, in the presence of back pain and/or radiculopathy, the selection of injection level and site (e.g. epidural space, facet joint, nerve root) depends on a more careful correlation of imaging findings and clinical symptoms. If there is no immediate decrease in pain intensity, a second injection can be made at a different site. A systematic approach is useful in diagnosing the source of pain and can aid in surgical planning.

Injection Procedures

Steroid injections are most commonly performed in joints, bursa, trigger points and spine. Image-guided spinal injections are performed for diagnostic (Figure 1) and therapeutic (Figure 2) purposes in patients whose pain has not responded to conservative treatment. Before arriving for the procedure, patients are requested to inform the Radiology Department if they are diabetic, take coumadin or other blood thinners, or have reactions to shellfish or to iodinated contrast agents. Patients are also requested not to take pain medication if their symptoms are mild.

Prior to the injection, a radiologist will question the patient about his or her symptoms and correlate them with MR and CT findings. Therefore, if the patient's most recent MR or CT scan was not performed at MGH, the patient is asked to bring a copy from the outside imaging center. Musculoskeletal radiologists have considerable experience in relating pain to imaging findings and may sometimes change the procedure after consultation with the referring physician.

	Lumbosacral	Thoracic	Cervical
Patient Position	Prone	Prone	Supine, with head turned sideways
Image-Guidance	Fluoroscopy	CT	Fluoroscopy

At the start of the procedure, after skin anesthesia, a needle is maneuvered to the injection target under image-guidance (Table 1). Fluoroscopy is used in most pain-management procedures. CT guidance is available if necessary. The gauge and length of the needle depends on the site of injection. Correct needle positioning is confirmed using the combination of imaging and the injection of a small amount of iodinated contrast material. The contrast fills the targeted space or outlines the nerve when positioned properly. Then a mixture of short acting anesthetic (bupivacaine) and steroid (betamethasone) is injected.

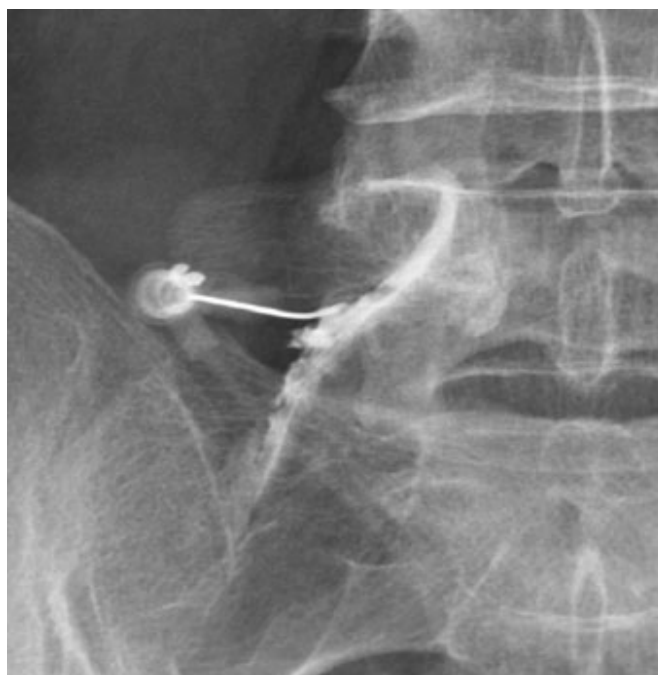


Figure 2. In this patient, left L5 radiculopathy correlated with left-sided L4-5 disk herniation on MRI. The fluoroscopy image shows the needle placed next to the left L5 nerve with contrast material outlining the nerve and flowing into the spinal canal to the level of the L4-5 disk. Pain decreased from 8/10 to 1/10 over 5 days.

In the spine, patients can experience their typical pain symptoms temporarily, adding to the diagnostic value of the procedure. Patients are asked to assess changes in their pain shortly after each injection. Pain relief immediately following the procedure is diagnostic of a problem at the site of injection and predicts successful action of the steroid. Longer lasting pain relief due to the effects of the steroid will not begin for 1-2 days.

After the procedure, patient activity depends on the injection site. Following spine injection, the patient is not permitted to drive but may leave the hospital under adult supervision. The anesthetic can cause temporary leg or arm weakness or numbness. Rarely, symptoms can be worse for a while after the procedure. During this time, it is recommended that activity be minimized.

Complications

Complications are infrequent but can include bleeding and infection at the injection site. An allergic reaction to iodinated contrast agent or to the anesthetic is a rare occurrence. The short-acting anesthetic may cause temporary arm weakness after cervical injection or leg weakness after lumbar injection. Pain can be temporarily worsened by the procedure. In diabetics, blood glucose levels often increase during the week following steroid injection. Since the steroid can take 5-7 days to reach maximum effectiveness, we ask patients to avoid especially vigorous activities that might stir up inflammation and prohibit the steroid from reaching its full potential effect. There do not appear to be any long-term consequences of multiple injections of betamethasone, but injections should not be repeated within 2 weeks to avoid side effects.

Scheduling

Physicians who wish to refer patients to Musculoskeletal Radiology for image-guided injections can schedule patients using Radiology Order Entry system, <http://mghroe> or can call the Musculoskeletal Imaging Division at 617-726-7717 or 617-724-7246 (4-PAIN). The procedures are performed in the Yawkey Center for Outpatient Care on the main MGH campus. Same day scheduling is available.

Further Information

For further questions on image-guided interventions for musculoskeletal pain, please contact [William E. Palmer, M.D.](#), Musculoskeletal Division, MGH Department of Radiology at 617-726-7717.

We would like to thank William E. Palmer, M.D., Frederick L. Mansfield, M.D., and Allan H. Goroll, M.D., for their advice on this topic.

References

- Aguirre, DA, Bermudez, S and Diaz, OM. (2005) *Spinal CT-guided interventional procedures for management of chronic back pain*. J Vasc Interv Radiol **16**: 689-97
- Boswell, MV, Trescot, AM, Datta, S, et al. (2007) *Interventional techniques: evidence-based practice guidelines in the management of chronic spinal pain*. Pain Physician **10**: 7-111
- Fenton, DS and Czervionke, LF (2003). *Image-Guided Spine Intervention*. Philadelphia, PA, Saunders.
- Silbergleit, R, Mehta, BA, Sanders, WP and Talati, SJ. (2001) *Imaging-guided injection techniques with fluoroscopy and CT for spinal pain management*. Radiographics **21**: 927-39; discussion 940-2

©2007 MGH Department of Radiology

Janet Cochrane Miller, D. Phil., Author
Raul N. Uppot, M.D., Editor