



## When Should Breast MRI Be Used?

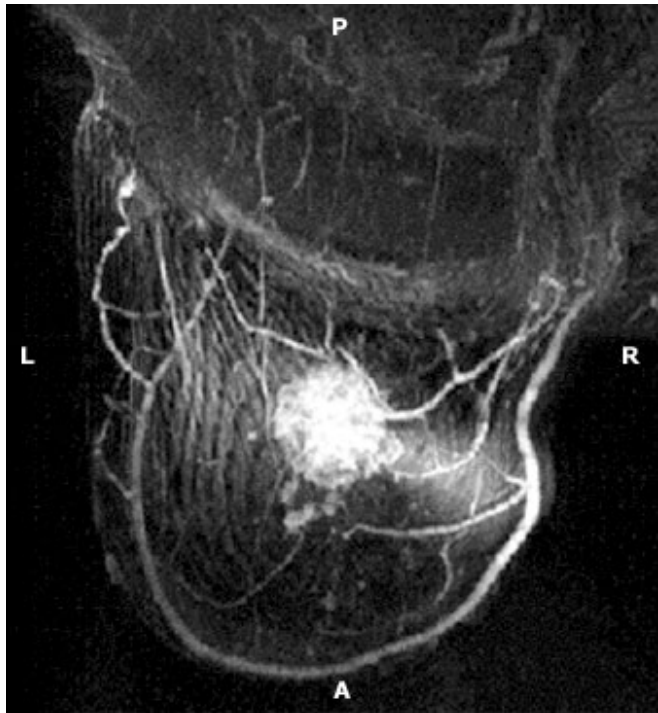
- Women at high genetic risk for breast cancer or with  $\geq 2$  first degree relatives with breast cancer may benefit from MRI screening
- Breast MRI is appropriate when results from clinical examination, mammography, and ultrasound are inconclusive and the radiologist suggests its use for further evaluation
- MRI may be appropriate for evaluation of women with diagnosed breast cancer to determine extent of disease or to monitor neo-adjuvant therapy
- MRI is the best way to find occult breast cancer in a woman who presents with metastatic disease thought to have originated in her breast
- MRI is appropriate if rupture of breast implants is suspected

Although MRI is a sensitive method for detecting breast tumors, there is, as yet, no evidence showing that MRI screening saves lives, as has been demonstrated for mammography. Furthermore, current treatment of most patients whose cancers were detected by mammography screening or palpation is so effective that relatively few die from this disease. In those cases where treatment is not successful, it is usually due to metastasis before detection, which can occur even when tumors seem small when first detected. Therefore, finding a tumor earlier may not necessarily result in a better outcome. In addition, MRI screening of the general population would not only be extremely costly but would also result in many women with benign lesions undergoing unnecessary biopsy.

### MRI Screening for High Risk Patients

Women who may benefit from MRI screening are those who are known to be at high genetic risk for breast cancer (carriers of the BRCA1, BRCA2, TP53, or PTEN genes) or who have two or more first degree relatives diagnosed with breast cancer. These women often develop cancer at an earlier age and have aggressive forms of cancer.

Mammography is quite effective, but not as sensitive in detecting cancers in these women because they have dense breast tissue that can sometimes hide a tumor on a mammogram, whereas MRI is virtually uninfluenced by breast density. On the other hand, mammography can find calcifications that can indicate an early cancer, and these cannot be seen by MRI. In one study in a high risk population population, the sensitivity of MRI for detecting all cancers was 71% (see box) and 80% for detecting invasive cancers.



MRI demonstrates large cancer vascularity

Since some cancers are not detected by MRI but can be seen by mammography, mammography as well as MRI is advisable for screening this population. As with the general population, there are no studies that prove that MRI screening of women at high risk for cancer will save lives, but given their very high level of risk, many feel that screening them with MRI is reasonable.

### Sensitivity and Specificity of Examinations for Breast Cancer in a High Risk Population\*

	Clinical Examination	Mammography	MRI
Sensitivity	18%	40%	71%
Specificity	98%	95%	90%

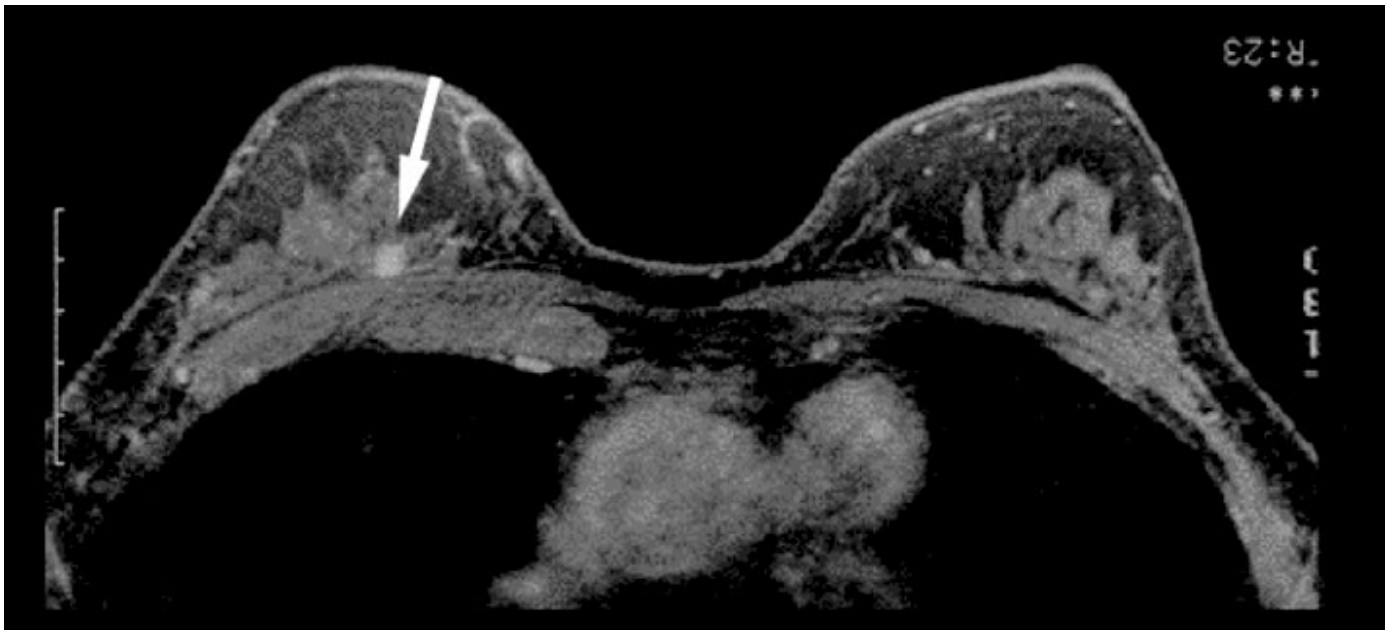
\*Women with genetic or familial predisposition to breast cancer

### Women with Recently Diagnosed Breast Cancer

Women who have recently been diagnosed with breast cancer may benefit from MRI because it shows more extensive disease than first detected in about 20% of women. Therefore, without MRI, patients are at risk of incomplete surgical removal of tumors and some will have to return for further surgery after pathologic examination determines that the margins were not clear.

MRI also detects the presence of a second ipsilateral cancer in about 10% of women with recently diagnosed breast cancer. There is, however, a potential downside to MRI in evaluating these women because treatment of two ipsilateral tumors requires mastectomy. Modern therapy has reduced the recurrence rates for women who undergo lumpectomy and radiation without MRI evaluation to under 2% at 10 years. Clearly, some women who may have had unsuspected additional foci of cancer were successfully treated without requiring a mastectomy.

About 2% of women diagnosed with breast cancer will develop cancer in the contralateral breast within a year and there is a subsequent risk of 0.5-1% per year. MRI of the contralateral breast detects tumors in about 5% of women with recently diagnosed breast cancer, even when clinical examination and mammography are negative. Because simultaneous cancer in the contralateral breast is associated with a high risk of metastasis (16%) and fatality (7%), patients whose cancers are detected early may benefit from prompt treatment.



Magnetic Resonance Imaging - Unsuspected cancer detected by MRI alone (arrow)

### MRI to Monitor Neo-adjuvant Chemotherapy

In patients with more advanced cancers, neo-adjuvant chemotherapy is often necessary to shrink the tumor before surgery. In these patients, MRI is advised to measure the tumor before treatment, during, and after neo-adjuvant chemotherapy. If MRI indicates that the chosen therapy has not resulted in tumor shrinkage after a course of treatment, then an alternative therapy may be selected.

### Women with Conditions Not Amenable to Conventional Imaging

Women who have had previous surgery for breast cancer, have silicone implants, or have radiographically dense breasts may have inconclusive results from clinical examination, mammography, and ultrasound. When these conventional evaluation methods are inconclusive, the radiologist will recommend an MRI if

it is likely to provide more diagnostic information. Breast MRI can distinguish between scar tissue and recurrent cancer and its image quality is not significantly impaired by dense tissue or implants.

Because MRI is more sensitive for cancer than mammography, it is the method of choice in a patient presenting with metastatic disease thought to be of breast origin. In addition, MRI is the best imaging modality for determining whether a silicone breast implant has ruptured, which may be suggested by breast pain after trauma.

## Scheduling

Breast MRI is performed on the Main Campus in the Avon Breast Evaluation Center, WACC219 , Mass General Imaging-Chelsea, Mass General West Imaging - Waltham, and Mass General MRI in the Charlestown Navy Yard. Examinations at all sites can be scheduled through the Radiology Order Entry system, <http://mghroe/> or by calling 617-724-9729.

## Further Information

For further questions, please contact, [Daniel B. Kopans, M.D.](#), Director of Breast Imaging in the Avon Breast Evaluation Center, at 671-726-3093. We would also like to thank Michelle C. Specht, M.D., Surgical Oncology, for her assistance and advice for this issue.

## References

American College of Radiology (2004). *ACR practice guideline for the performance of magnetic resonance imaging (MRI) of the breast.* ([Download .pdf](#))

Kriege, M, Brekelmans, CT, Boetes, C, Besnard, PE, *et al.* (2004) *Efficacy of MRI and mammography for breast-cancer screening in women with a familial or genetic predisposition.* N Engl J Med **351**: 427-37

Liberman, L, Morris, EA, Dershaw, DD, Abramson, AF and Tan, LK. (2003) *MR imaging of the ipsilateral breast in women with percutaneously proven breast cancer.* AJR Am J Roentgenol **180**: 901-10

Liberman, L, Morris, EA, Kim, CM, Kaplan, JB, *et al.* (2003) *MR imaging findings in the contralateral breast of women with recently diagnosed breast cancer.* AJR Am J Roentgenol **180**: 333-41

©2005 MGH Department of Radiology

*Janet Cochrane Miller, D. Phil., Author*  
*Susanna I. Lee, M.D., Ph.D., Editor*