



Imaging for Male Infertility

- **After male infertility has been diagnosed, ultrasound is the imaging modality of choice for evaluation of male genital anatomy for possible causes**
- **Scrotal ultrasound evaluates the testicules, epididymii, and proximal vas deferens, including abnormalities secondary to distal genital duct obstruction**
- **Prostate ultrasound evaluates the distal vas deferens, vasa ampullae, seminal vesicles, the prostate gland, and ejaculatory ducts for congenital absence, obstruction, and cysts**

Infertility in a couple is defined as the failure to conceive after 12 months of frequent unprotected intercourse. In approximately 50% of infertile couples, the problem is at least in part due to male infertility, which is initially recognized through semen analysis. If the man is sub-fertile, he is typically referred to a urologist for evaluation of possible causes of infertility. Patient history, clinical examination, and laboratory testing are all essential for evaluation. Ultrasound is the imaging modality of choice because it can adequately demonstrate all the essential parts of the male reproductive system. Although vasography is still regarded as the gold standard for visualizing the male reproductive tract, it is invasive and carries with it a risk of damage to the vas deferens and is, therefore, rarely used. MRI rarely provides information that cannot be obtained by ultrasound.

Both scrotal and prostate ultrasound examinations can be done at the same time but because the prostate examination is a more invasive (transrectal probe), referring physicians may prefer to schedule a scrotal ultrasound alone. These imaging examinations are performed to evaluate for disorders that obstruct sperm transport or to evaluate for congenital absence of the vas deferens. Together, these disorders account for 10-20 % of male infertility cases. In a small proportion of these cases, imaging identifies a potentially correctable cause of obstruction. More commonly, it serves to guide the selection of the best method for impregnating the female partner, such as sperm aspiration from the epididymis or seminiferous tubules followed by in vitro fertilization or intracytoplasmic sperm injection.

Scrotal Ultrasound

Scrotal ultrasound can be helpful in determining whether azoospermia is non-obstructive or obstructive (Table 1) because it can directly detect abnormalities in the mediastinum testis, epididymis, and the proximal

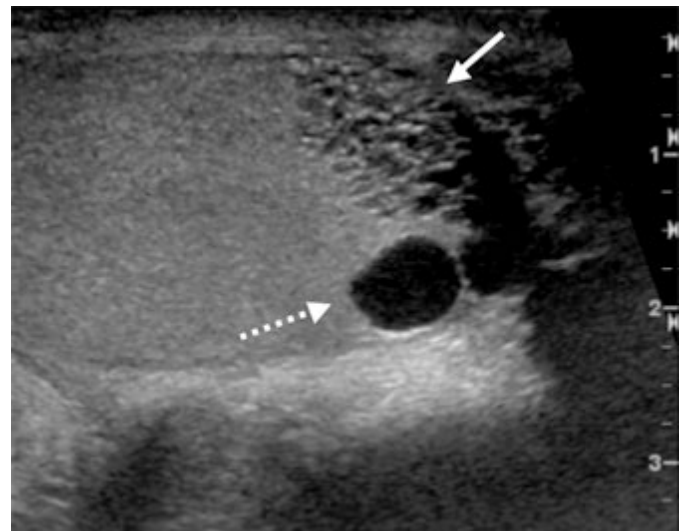


Figure 1. Ultrasound of the scrotum. Sagittal image of the left testicle demonstrates ectasia of the rete testes (solid arrow) with intratesticular cysts (dashed arrow). This finding, in association with azoospermia, is suggestive of an obstructive etiology and is helpful in directing further work-up in the setting of infertility.

Table 1. Scrotal ultrasound findings in infertile men
Testicular abnormalities
Absence
Atrophy
Cryptorchidism
Ectopic location
Abnormalities associated with obstruction, e.g. mediastinal cysts, enlarged volume
Epididymal abnormalities associated with obstruction, e.g. tubular ectasia
Epididymal hypoplasia, abrupt tapering shape
Varicoceles

vas deferens. It can also show secondary changes due to obstructive abnormalities in the distal genital duct. Epididymal abnormalities associated with obstruction include tubular ectasia, enlarged hypoechoic foci (suggestive of inflammatory masses), and abrupt tapering from the head to body or mid- to distal portions of the epididymis. Cysts may also be identified within the mediastinum testis. Appearance of one or more of these abnormalities is indicative of distal obstruction, with at least one report documenting a sensitivity of 82%, specificity of 100%, and accuracy of 88%.

Scrotal ultrasound is also used to examine the testes in at least two planes, the transverse and longitudinal; the size is measured and the echotexture compared to the other side. Testicular volume is significantly higher ($p < .05$) in those with obstructive azoospermia (median 11.6 cm³, range 7.7 - 25.8 cm³) compared to non-obstructive azoospermia (median 8.3 cm³, range 1.2 - 16.4 cm³). Also, if a testis is non-palpable, scrotal imaging can determine whether it is congenitally absent, cryptorchid, atrophic, or ectopic.

Perhaps most commonly, scrotal ultrasound has been used to confirm the presence of varicocele detected by physical examination or to find non-palpable varicoceles. It is well known that varicoceles are more common in infertile men compared to the general population. However, their significance as a cause of infertility is controversial.

Scrotal ultrasound is recommended before epididymal sperm aspiration because approximately one third of patients with vasal agenesis have hypoplasia of the distal two-thirds of the epididymis. Imaging can identify which portion of the epididymis is longest and most suitable for aspiration.

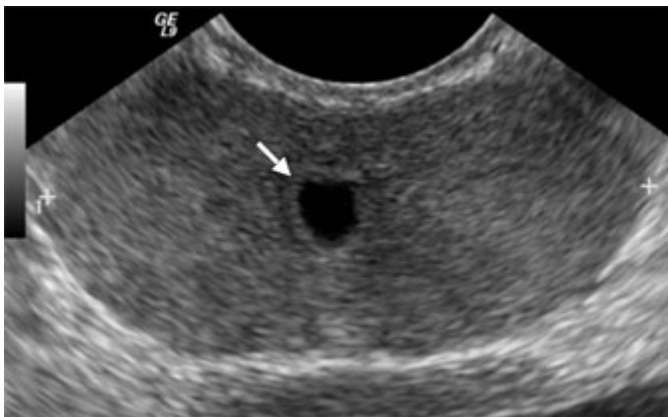


Figure 2. Transrectal ultrasound of the prostate. Transverse image of the prostate in a young male demonstrates a small midline cystic structure (arrow), thought to represent a utricle cyst. In addition to detecting cystic lesions, trans-rectal ultrasound of the prostate is also used to evaluate the seminal vesicles and the vas deferens for congenital abnormalities.

Prostate (Transrectal) Ultrasound

The prostate ultrasound examination is used to examine the distal vas deferens, vasal ampullae, seminal vesicles, prostate, and ejaculatory ducts. Anomalies of the vas deferens can range from complete congenital bilateral or unilateral absence of the vas deferens to vestigial remnants that appear as isoechoic or hyperechoic oval structures, less than 3 mm in diameter and located posterior to the bladder. Vasal agenesis is commonly associated with anomalies of the seminal vesicles and ejaculatory duct. Overall, vasal agenesis has been reported to occur in 1.0 - 2.5% of all infertile men but has been reported to account for 34% of men with low volume azoospermia (Table 2). Vasal agenesis is also associated with renal anomalies such as ipsilateral renal agenesis, crossed fused ectopia, or ectopic pelvic kidney. In addition, up to 82% of men with bilateral vasal agenesis have at least one detectable gene mutation for cystic fibrosis.

Ductal obstruction is indicated by abnormal echogenicity of the vas deferens, seminal vesicles, and/or ejaculatory duct. In some cases, the abnormalities can be subtle and diffuse while in others calcification is readily apparent. Calculi may develop in an otherwise normal duct or may develop secondary to obstruction with concretion of static cellular fluid and debris.

Obstructing cysts are most commonly seen in a periurethral location but can affect the seminal vesicles or the vas deferens. Midline periurethral cysts, also known as utricle cysts, are thought to be derived from an incompletely regressed müllerian duct. Ejaculatory duct cysts, derived from Wolffian ducts, typically contain sperm and can be confused with utricle cysts when they appear midline by ultrasound. Prostatic cysts, also known as retention or degenerative cysts, are more lateral in location and rarely reach sufficient size to compress the adjacent ejaculatory ducts and cause infertility. Seminal vesicle cysts, although rare, are associated with renal disorders and anomalies, including adult polycystic kidney disease, ipsilateral renal dysgenesis, duplication of the renal collecting system, ectopic insertion of the ureter, and ectopic location of the kidney.

Table 2. Prostate ultrasound findings in infertile men with low-volume azoospermia

None	25%
Congenital bilateral absence of the vas deferens	34%
Bilateral occlusion of ductal system by fibrosis or calcification	16%
Congenital unilateral absence of the vas deferens	11%
Obstructing cysts of the ductal system or prostate	9%
Ductal obstruction due to calculi	4%

Radiologic and Surgical Interventions

In some cases, fertility can be restored to patients with cysts that are occluding part of the ductal system by decompression, provided that the ductal system itself is intact. In these cases, ultrasound guided aspiration of the cystic contents is used to relieve the pressure, which can allow the ducts to open and to function normally. In cases of distal ductal anomalies, it is sometimes possible to restore fertility surgically. Alternatively, microscopic sperm aspiration followed by *in vitro* fertilization or intra-cytoplasmic injection may be successful in producing viable embryos for implantation.

Scheduling

Scrotal and prostate ultrasound may be ordered through ROE at the MGH Main Campus, Mass General West Imaging Waltham, and MGH Chelsea Health Center, or by telephone 617-724-XRAY (9729) for all locations.

Further Information

For further questions, please contact [Joshua Stuhlfaut, M.D.](#), Abdominal Imaging and Intervention, MGH Department of Radiology

We would like to thank Dr. Stuhlfaut and Pablo Gomery, M.D., Department of Urology, for their assistance and advice for this issue.

References

- Beddy, P, Geoghegan, T, Browne, RF and Torreggiani, WC. (2005) *Testicular varicoceles*. Clin Radiol. **60**: 1248-55
- Brugh, VM, 3rd and Lipshultz, LI. (2004) *Male factor infertility: evaluation and management*. Med Clin North Am. **88**: 367-85
- Kuligowska, E and Fenlon, HM. (1998) *Transrectal US in male infertility: spectrum of findings and role in patient care*. Radiology. **207**: 173-81
- Moon, MH, Kim, SH, Cho, JY, Seo, JT and Chun, YK. (2006) *Scrotal US for evaluation of infertile men with azoospermia*. Radiology. Published online before print, February 7, 2006

©2006 MGH Department of Radiology

Janet Cochrane Miller, D. Phil., Author
Susanna I. Lee, M.D., Ph.D., Editor