



Imaging for Sinusitis

- **Imaging for patients with symptoms of acute or subacute sinusitis is not recommended unless a complication or an alternate diagnosis is suspected**
- **Definitive diagnosis of chronic sinusitis requires confirmation of inflammation by imaging or nasal endoscopy, however empirical treatment without imaging based upon a clinical diagnosis may be appropriate for many patients**
- **Multidetector CT (MDCT) is the imaging modality of choice because it clearly shows air spaces, opacification of sinuses, and bony anatomy**
- **MR imaging is indicated in conjunction with CT when extra-sinus complications of sinusitis are suspected**

Each year, nearly 31 million people in the USA are diagnosed with sinusitis, defined as an inflammatory process involving the mucous membranes of the paranasal sinuses. Symptoms of sinusitis include mucopurulent nasal discharge, nasal congestion, facial pain, pressure or fullness, and decreased perception of taste or smell. These symptoms result in substantial adverse effects on mood, physical functioning, energy level, and social functioning.

Sinusitis is classified by the duration of symptoms into acute (<4 weeks), subacute (4-12 weeks), chronic (≥ 12 weeks), or recurrent acute sinusitis (≥ 4 episodes per year of acute bacterial sinusitis without signs or symptoms of sinusitis between episodes) (Table 1). The distinction between viral and bacterial sinusitis cannot be made based on the presence of a purulent nasal discharge but is made based on illness pattern and duration. If the symptoms are present 10 days or more after the onset of respiratory symptoms or worsen within 10 days after an initial improvement, then the diagnosis is presumed to be bacterial sinusitis. Chronic sinusitis, which affects 14-16% of the adult population, is one of the most common chronic diseases. Furthermore, chronic sinusitis or recurrent acute sinusitis implies persistent disease that is not likely to resolve without intervention tailored to the etiology.

Imaging for Sinusitis

The American Academy of Otolaryngology, in its 2007 clinical practice guideline, recommended against diagnostic imaging for patients with acute or sub-acute sinusitis unless a complication or alternate diagnosis is suspected (Table 1). However, imaging or nasal endoscopy is recommended for symptoms of chronic sinusitis because this condition may be associated with predisposing factors that contribute to illness persistence, recurrence, or both. Imaging or nasal

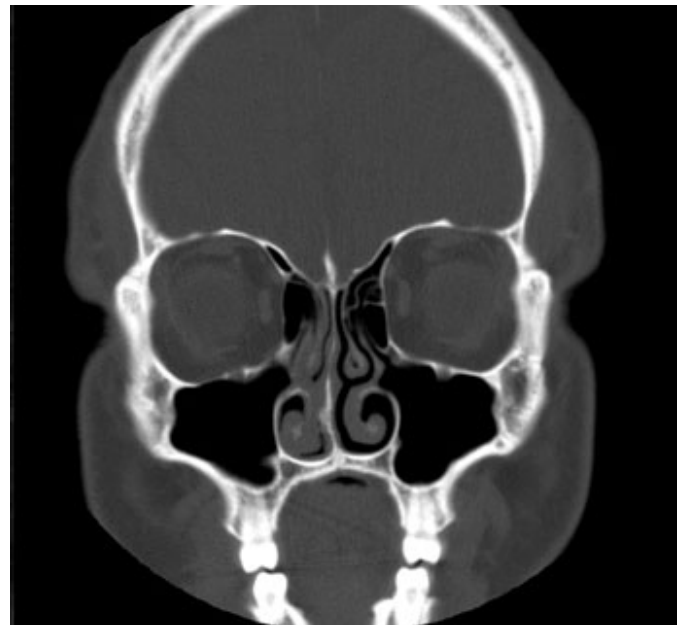


Figure 1. Coronal CT image of showing normal air-filled sinuses with no evidence of bone destruction or soft tissue masses.

endoscopy are needed to confirm the diagnosis, because the symptoms of chronic sinusitis overlap with other common conditions, including allergic and non-allergic rhinitis, nasal septal deformity, and non-rhinogenic causes of facial pain. Furthermore, imaging is useful in helping to guide treatment and in identifying extrasinus abnormalities associated with chronic sinusitis. Although there is a strong association between allergy and sinusitis, identification of allergies does not imply they are the only cause of sinusitis, and other factors should be considered.

Table 1. Characterization of Sinusitis and its Symptoms

Chronic Rhinosinusitis

Twelve (12) or more weeks of **two or more** of the following symptoms:

- Mucopurulent discharge (anterior, posterior, or both)
- Nasal obstruction (congestion)
- Facial pain, pressure, or fullness
- Decreased sense of smell and/or perception of taste

AND documentation of inflammation by one of the following:

- Nasal endoscopy
- Imaging (CT)

Recurrent Acute Rhinosinusitis

Four (4) or more episodes per year of acute bacterial rhinosinusitis, without signs or symptoms of rhinosinusitis between episodes

Each episode should be caused by, or be presumed to be caused by a bacterial infection because:

- Acute symptoms were present 10 days or more beyond onset of upper respiratory symptoms *or*
- Symptoms or signs of acute sinusitis worsen within 10 days of an initial improvement

Complicated Sinusitis

Sinister features include:

- High fever and severe headache
- Abnormal vision (diplopia, blindness)
- Proptosis
- Change in mental status
- Periorbital edema or erythema
- Unilateral signs (e.g. polyp or mass)
- Bleeding
- Maxillary paraesthesia

The presence of two or more of the characteristic signs or symptoms of sinusitis for ≥ 12 weeks is highly sensitive for chronic sinusitis but is not specific. Using CT imaging as the criterion standard, estimates of the prevalence of chronic sinusitis in those referred for evaluation of this condition ranges from 65% to 80%. Therefore, most ENT specialists believe that a definitive diagnosis of chronic sinusitis requires imaging or nasal endoscopy. However, European guidelines addressed at primary care givers suggest that empirical treatment without imaging is appropriate in many cases, although anterior rhinoscopy or more detailed endoscopy should be performed to identify polyps. They recommend a trial of topical nasal corticosteroids, nasal douching, and use of antihistamines in allergic patients without further diagnostic tests in patients without, or with less symptomatic polyps. Those patients who do not respond to this treatment should be referred for CT imaging or endoscopy.

Recurrent acute sinusitis should be distinguished from isolated acute bacterial sinusitis because of the greater burden of disease and different approach to management. Patients with recurrent acute sinusitis may benefit from diagnostic tests, such as CT imaging, nasal endoscopy, and allergy and immune testing. For recurrent acute sinusitis, imaging is most useful between episodes in order to identify anatomic variants that may predispose the patient to recurrent disease. CT is also indicated if intraorbital complications are suspected.

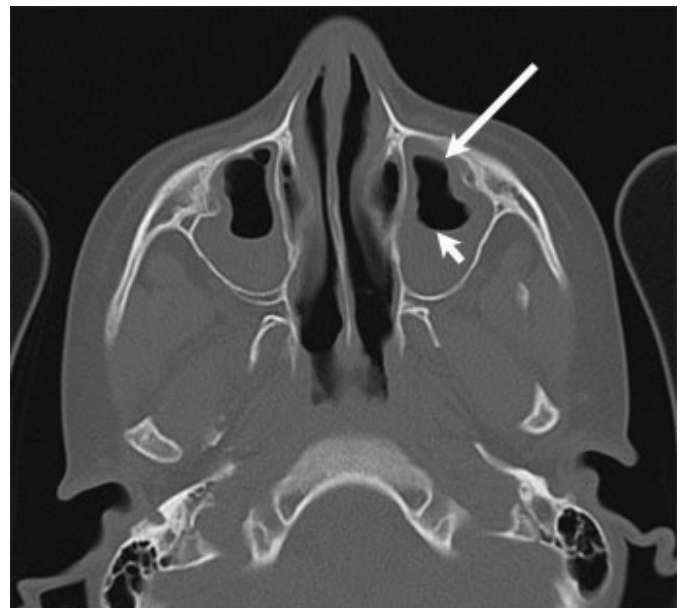


Figure 2. CT demonstrates mucosal thickening (long arrow), and an air-fluid level (short arrow), findings seen in sinusitis.

CT Imaging

The high contrast of CT images clearly shows air spaces, opacified sinuses, and the fine structural architecture of bony anatomy (Figure 1). It is,

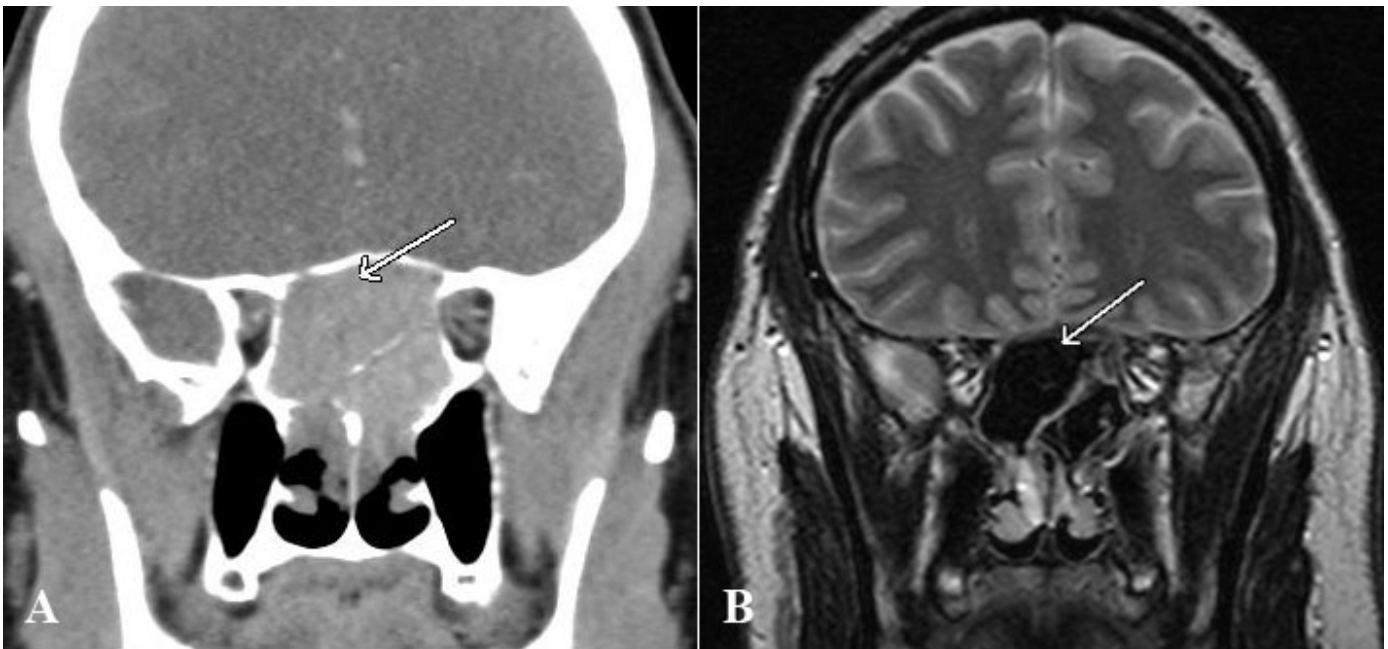

Figure 3. (A) CT in a patient with allergic fungal sinusitis leading to a sphenoid mucocoele. Note the markedly hyperdense secretions and the expanded bony margin (arrow). **(B)** T2 weighted MRI in the same patient demonstrates the limitations of MRI in the evaluation of benign sinus disease: the inspissated secretions filling the sphenoid sinus are so proteinaceous that they are very hypointense on T2 weighted imaging (arrow) and give the false impression that the sinus is aerated.

therefore, the gold standard for delineating inflammatory sinus disease and evaluating mucosal abnormalities, sinus ostial obstruction, anatomic variants, and sinonasal polyps. Multidetector CT (MDCT) allows objective assessment of the patency of intercommunicating passages and shows how anatomic variants, inflammatory disease, or both may affect patency. Anatomic variants that may predispose to disease include septal deviation, concha bullosa, Haller cells, hypoplasia of the maxillary sinus, and narrowing or obstruction of the osteomeatal complex. MDCT can show anatomic structures that are not visible by physical examination or nasal endoscopy and is, therefore, the study of choice for the surgeon who is considering or planning functional endoscopic sinus surgery.

The characteristic features in CT images of both chronic and acute sinusitis include air-fluid levels, mucosal thickening, and opacification of the sinus cavities that are normally air-filled (Figure 2). Sclerotic, thickened bone in the sinus walls is characteristic of chronic sinusitis, although this feature is not seen in every case. The appearance of the mucosa is non-specific and the extent of inflammatory disease does not always correlate with the severity of symptoms or their effects on the quality of life. Therefore, mucosal thickening should be interpreted in the context of clinical examination or nasal endoscopy or both. Dense opacification or opacification with inhomogeneous "hyperdensities" is suggestive of thick, inspissated mucus and is a feature of "allergic fungal sinusitis" (Figure 3A) a condition associated with type I IgE-mediated hypersensitivity to one or more fungi. This condition accounts for less than 10% of chronic sinusitis cases but is associated with severe persistent disease. Invasive fungal disease is rare unless the patient is immunocompromised or has poorly controlled diabetes.

MDCT allows the reconstruction of coronal and sagittal images from a single imaging data set. When a low-radiation-dose protocol is used, the radiation dose from CT is comparable to the standard four-view plain radiographic series. Coronal reconstructions provide views similar to those seen by endoscopy. Axial and sagittal reconstructions are especially useful in delineating certain anatomic abnormalities, such as an Onodi cell, or extrasinus abnormalities. These findings are important to recognize prior to sinus surgery.

CT can also play an important role in excluding the presence of aggressive infections or neoplastic disease. Characteristics that are suggestive of malignancy include osseous destruction, extra-sinus extension, and local invasion. If these findings are noted, MR imaging should be performed to differentiate between benign obstructed secretions and tumor and to assess for intracranial spread.

MR Imaging

If complications of sinusitis are suspected, superior soft-tissue contrast of MR imaging is recommended to evaluate skull base or intracranial invasion and to determine the relationship between invasive masses and vital structures, such as the optic nerve and the carotid artery (Figure 4). MR imaging is also useful for determining the extent or source of an infection, such as an orbital abscess, and it plays a vital role in the diagnostic evaluation of aggressive fulminant fungal sinus infections.

It should be noted that the MR appearance of sinus occlusion depends on the protein concentration of the mucus, which is related to the degree of its desiccation. If the protein concentration is high, T2 images are hypointense and can be mistaken for normal, air-filled sinuses (Figure 3B). Hyperdensities seen in an opacified sinus by CT imaging, which is a classic feature

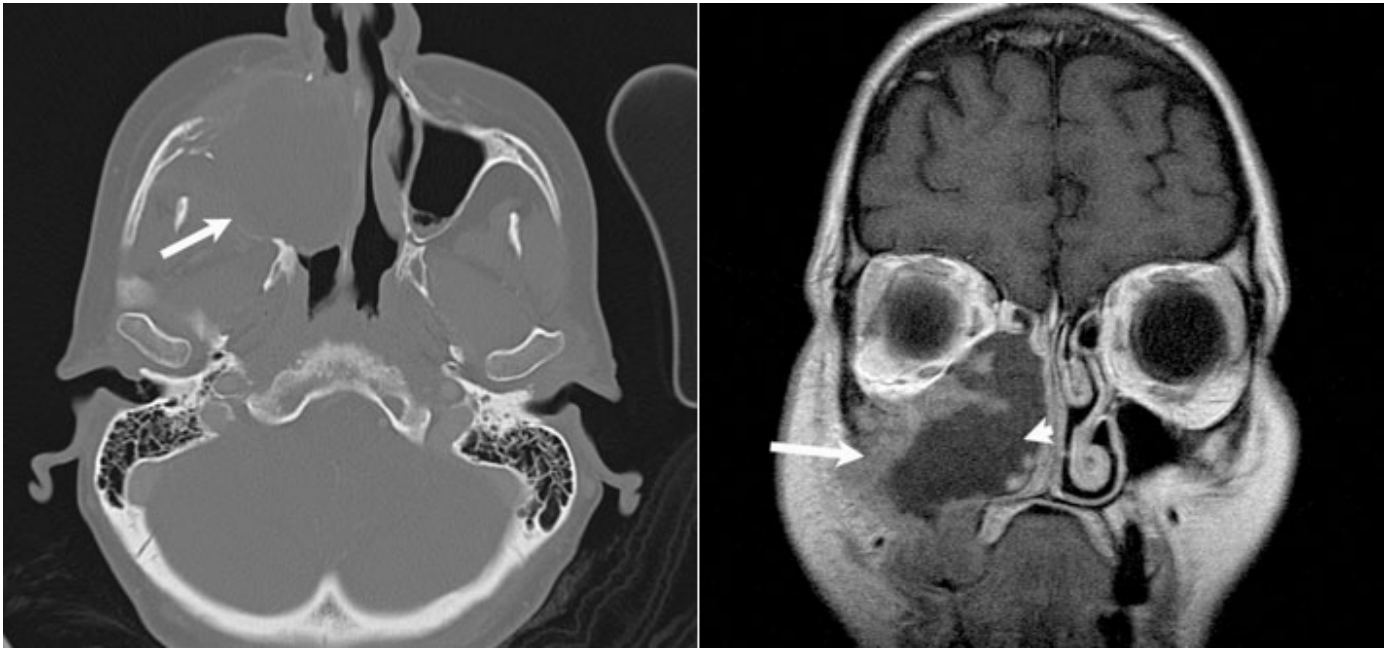

Figure 4. (A) CT of a patient with maxillary sinus cancer demonstrates bony destruction, (arrow) a hallmark of malignancy. **(B)** MRI in the same patient more accurately distinguishes between the intermediately enhancing tumor (long arrow) lining the maxillary sinus and the non-enhancing secretions (short arrow) filling the maxillary sinus.

of allergic fungal sinusitis, often appear hypointense by T2-weighted MR imaging. Similar ranges in intensity may be observed in mucoceles, which also have varying concentrations of protein.

Scheduling

CT and MR examinations can be ordered through ROE (<http://mghroe>) or by telephone **617-724-XYRAY (9729)** for all locations. Both CT and MR are performed at the main campus as well as Mass General West Imaging, Waltham, and Mass General Imaging, Chelsea. MR examinations are also performed at Mass General Imaging, Charlestown Navy Yard.

Further Information

For further information on imaging sinusitis, please contact [Mary Beth Cunnane, M.D.](#), at **617-573-3842**.

We would like to thank Mary Beth Cunnane, Neuroradiology Division, Vartan Vartanians, MD, Clinical Research Associate, Mass General Imaging, Hugh Curtin, MD, Radiologist-in-Chief, Massachusetts Eye and Ear Infirmary, Daniel L. Hamilos, Rheumatology, Allergy, and Immunology Division, Department of Medicine, and Stacey Gray, MD, Otolaryngologist, Massachusetts Eye and Ear Hospital, for their advice and assistance in the preparation of this article.

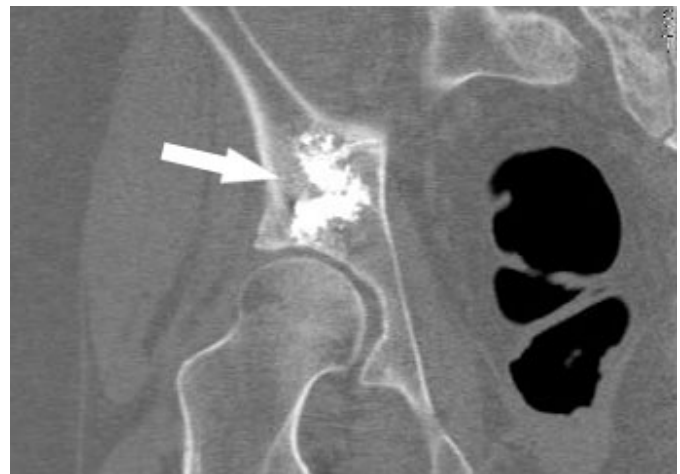

Figure 5. Post-procedure CT scan after augmentation of right acetabulum showing satisfactory placement of cement.

References

Ah-See, KW and Evans, AS. (2007) *Sinusitis and its management*. *BMJ* **334**: 358-61

Mafee, MF, Tran, BH and Chapa, AR. (2006) *Imaging of rhinosinusitis and its complications: plain film, CT, and MRI*. *Clin Rev Allergy Immunol* **30**: 165-86

Momeni, AK, Roberts, CC and Chew, FS. (2007) *Imaging of chronic and exotic sinonasal disease: review*. *AJR Am J Roentgenol* **189**: S35-45; quiz S46-8

Rosenfeld, RM, Andes, D, Bhattacharyya, N, *et al.* (2007) *Clinical practice guideline: adult sinusitis*. *Otolaryngol Head Neck Surg* **137**: S1-31

Thomas, M, Yawn, BP, Price, D, *et al.* (2008) *EPOS Primary Care Guidelines: European Position Paper on the Primary Care Diagnosis and Management of Rhinosinusitis and Nasal Polyps 2007 - a summary*. *Prim Care Respir J* **17**: 79-89

©2009 MGH Department of Radiology

Janet Cochrane Miller, D. Phil., Author

Raul N. Uppot, M.D., Editor